

The First Total Artificial Heart



University of Utah Hospital

On the night of December 1-2, 1982, with a major winter storm howling outside, medical history was being made inside the University of Utah Hospital. This event was the implantation of the first destination total artificial heart (TAH) in a human being. That person, 61-year-old Barney Clark, was a retired Seattle dentist with family roots in Utah.

Dr. Clark's several year history of dyspnea and fatigability had been attributed to chronic obstructive pulmonary disease in a former smoker. However, 2 1/2 years before admission, a

diagnosis of heart failure was made associated with atrial fibrillation with a rapid ventricular response. In-patient treatment for recurrent heart failure with paroxysmal ventricular tachycardia (VT) was required 1 ½ years before admission. Coronary angiography and left ventriculography established a diagnosis of advanced, non-ischemic dilated cardiomyopathy with an ejection fraction of 23%. Because



**Jeffrey L. Anderson, MD:
Barney Clark's Cardiologist**


of symptomatic progression of heart failure, Dr. Clark was referred to the author at LDS Hospital in Salt Lake City, near family members, for investigational inotrope therapy (amrinone), but this caused hypotension and exacerbated atrial and ventricular tachyarrhythmias. Endomyocardial biopsy showed low-grade cellular and humoral myocarditis, and a course of immunosuppressant therapy (prednisone and azathioprine) was begun with initial improvement. However, clinical deterioration resumed, with low-output failure and edema, 6 ½ months later, leading to hospitalization for IV diuretics and dobutamine. Clinical improvement was only marginal, leaving him in class IV heart failure.



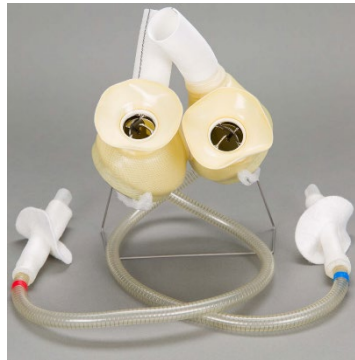
**Calves implanted with total artificial hearts.
Don B. Olsen, DVM lead the animal research effort**

An opportune meeting occurred 3-4 months prior to the final admission between the author and Dr. William DeVries in a hot tub after a workout at the old Einar Nielsen Fieldhouse on University campus. Dr. DeVries indicated readiness to select a patient for the first TAH implant, and Dr. Anderson provided the name of Dr. Clark as a potential candidate. A meeting between Dr. DeVries and Dr. Clark and spouse (Una Loy) was arranged in October 1982, where a thorough review of the TAH program occurred. The Clarks followed this a short time later with a visit to the nearby animal laboratory at the old St. Mark's Hospital complex to see calves with pneumatically powered artificial hearts. They also visited the manufacturing area where TAHs were in various stages of assembly. The Clarks were impressed with the TAH program and agreed to discuss with family members and personal physicians before enrolling. Ongoing deterioration in Dr. Clark's cardiac status in late November led to the final decision to proceed.

A long road had led to the development of the "Jarvik-7 model Utah Heart". Pioneering efforts began with Dr. Willem Kolff, a Dutch immigrant who was recruited to the University of Utah and became recognized worldwide as a leader in artificial organs, including artificial kidneys (efficient dialysis units)



Willem (Pim) Kolff, MD, PhD:
Chief of the University of Utah's
Division of Artificial Organs and
Institute for Biomedical
Engineering

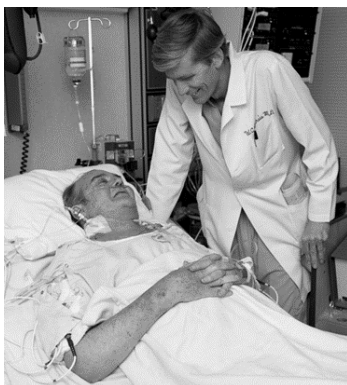

Jarvik-7 Total Artificial Heart

and, subsequently, the artificial heart. With the help of many co-investigators, new materials and methods, progress occurred gradually. Dr. Don B Olsen, a superbly talented veterinary surgeon then joined the team to lead a large animal research effort. In 1972, Dr. Robert Jarvik (starting in his freshman year in medical school) began working on innovative design improvements, which continued to evolve, guided by testing in calves, over the subsequent decade. Contributing to animal testing of the final iterations of the TAH, were chief cardiovascular surgeon William DeVries and newly trained assistant surgeon Lyle Joyce, who completed the complement of TAH team members.

Meanwhile, with his heart failure entering the terminal stage, Dr. Clark was admitted to University Hospital for a final “tune-up” prior to surgery. This included IV furosemide in combination with metolazone, which yielded a minimal diuretic response. IV dobutamine was interrupted because of bursts of VT. A rapid, sustained run of VT, occurring on the 3rd hospital day, resulting in transient loss of consciousness, was terminated by chest thumping. With death appearing imminent that evening, an emergent call went out to the operating team. Dr. Clark was wheeled into the operating suite, general anesthesia was induced, cardiopulmonary bypass was initiated, and the TAH operation began. The operating-room team consisted of surgeons Bill DeVries, Lyle Joyce, and Don Olsen; anesthetist Nathan Pace; cardiologists Fred Anderson and Jeff Anderson; perfusionist Doug Smith; heart-driver engineer Steve Nielsen; heart-driver manager Larry

Hastings; advisor Robert Jarvik; and nurses Gayle Baldwin and Diane Karsten. And while Salt Lake City slept, the operation was performed. The heart was excised at the level of the atria near the AV valves; connections to the great vessels were made with vascular grafts; the left and right artificial ventricles were installed and connected to the atrial cuffs and great-vessel grafts; the internal drive lines were tunneled subcutaneously to exit the left flank and connected to the drive lines of the pneumatic heart driver. The operation was complicated by increased tissue friability and hemorrhage and dysfunction of the prosthetic mitral valve, which required replacement of the left prosthetic heart. However, at 4:15 am the 7-hour operation was complete, and the patient readily came off cardiopulmonary bypass.



William DeVries, MD:
Barney Clark's Surgeon
Barney Clark: Recipient of
the first total artificial heart

Dr. Clark opened his eyes and moved his extremities on command 3 hours later and was extubated on post-operative day (POD) 2, conscious and able to communicate with family and physicians. With a well-functioning TAH a brisk diuresis ensued. Daily updates by Dr. Chase Peterson, VP for Health Sciences (and later, University of Utah President), began to a large and enthusiastic group of assembled press personnel who reported to a fascinated public. Barney Clark's course thereafter was, unfortunately, frequently complicated, and ended in his death on POD 112. These complications included rupture of pulmonary blebs, episodes of acute tubular necrosis and



William DeVries, MD

renal insufficiency, idiopathic seizures and altered mental status, and fracture of a mitral valve strut, requiring replacement of the left prosthetic heart. However, by the end of the third month, pulmonary and renal function had stabilized, mental status was intact, appetite had improved, physical therapy was progressing, and plans for eventual discharge were envisioned. This stable state was interrupted on POD 92 by diarrhea and projectile vomiting with aspiration and pneumonia treated with respiratory support and antibiotics. On days 109-111, recurrent fever, hematochezia, progressive renal failure, and hemodynamic instability occurred, leading to circulatory shock and death on POD 112 despite intact function of the TAH system. Autopsy confirmed a diagnosis of pseudomembranous colitis, ATN, and chronic emphysema.



Clinical use of the total artificial heart

WC DeVries, JL Anderson, LD Joyce, FL Anderson, EH Hammond, RK Jarvik, and WJ Kolff

20-Year Intense Effort: U of Utah Bioengineering, Cardiology & CT Surgery

reported here indicates the feasibility of relatively long-term cardiovascular support with a totally implanted artificial heart in a human being. Despite the relatively complicated postoperative course in our patient, the overall experience of 112 days nonetheless leads to an optimistic appraisal of the future potential for total artificial-heart systems. Much still remains to be explored with respect to the engineering, medical, socioeconomic, and ethical aspects of artificial-heart transplantation." Looking back after almost 40 years has validated this statement, although progress has taken us in directions not envisioned then. The development of small, durable, well-tolerated left ventricular assist devices to support cardiac function has obviated the need for replacement of the heart with TAH systems in most heart failure patients. Nevertheless, current TAH systems remain the preferred and often only option in a minority of patients.

The demonstration of the feasibility of supporting a damaged heart mechanically may be the greatest positive outcome and lesson of the "Barney Clark" story at the University of Utah. This demonstration encouraged the continued pursuit of a whole new field of bioengineering. This pursuit has led to our current ability to provide benefit through mechanical support to advanced heart failure patients not only in Utah but to thousands of other patients each year worldwide.

Jeffrey L Anderson, MD

June 1, 2020

References:

DeVries WC, Anderson JL, Joyce LD, Anderson FL, Hammond EH, Jarvik RK, Kolff WJ. Clinical Use of the Total Artificial Heart. *N Engl J Med* 1984; 310:273-8.

Don B Olsen. True Valor. Barney Clark and the Utah Artificial Heart. University of Utah Press. 2015.